

Fortnightly review

Male pattern androgenetic alopecia

Rodney Sinclair

Androgenetic alopecia is characterised by progressive, patterned hair loss from the scalp. Recently the pathogenesis and genetic basis of the hair loss have been better understood, as has the distress experienced by men who have lost their hair. There have also been breakthroughs in the treatment of androgenetic alopecia.

The transition of some terminal hairs into vellus hairs is a universal physiological secondary sexual characteristic.¹ Androgenetic alopecia becomes a medical problem only when the hair loss is subjectively seen as excessive, premature, and distressing.

The prerequisites for premature androgenetic alopecia are a genetic predisposition and sufficient circulating androgens.² Eunuchs do not go bald.³ Every white man possesses the autosomal inherited predisposition,⁴ and 96% lose hair to some degree,⁵ but because of the variability of gene expression far fewer have appreciable premature hair loss.

Methods

This article is based largely on my experience in the management of hair loss. Original articles and expert reviews from major journals cited in Medline between 1966 and 1997 have been supplemented by information and articles cited in recently published textbooks. The following keywords were used for the Medline search: androgenetic alopecia, androgenic alopecia, common baldness and balding, premature baldness and balding, hereditary balding and baldness, male pattern and female pattern alopecia, hair loss, balding and baldness. From the abstracts of the 316 articles identified, I selected 126 references for detailed examination.

Prevalence and clinical features

By the age of 30, 30% of white men have androgenetic alopecia; by the age of 50, 50% do.⁵ White men are four times more likely to than black men develop premature balding.⁶

Androgenetic alopecia produces patterned hair loss,⁵ beginning with bitemporal recession of the frontal hair line, followed by diffuse thinning over the vertex. Over time there is complete hair loss centrally on the vertex, producing a bald patch. The patch enlarges and joins the receding frontal hair line, leaving behind an island of hair on the frontal scalp.

Summary points

Androgenetic alopecia is a specific type of hair loss mediated by systemic androgens and genetic factors

Recent advances in understanding of the biology of hair follicles have shed light on the pathogenesis of androgenetic alopecia

Though most men learn to deal with their androgenetic alopecia without it impairing their psychosocial functioning, some men tolerate hair loss poorly and have a negative overall body image and diminished quality of life

Safe and effective treatments are currently available for androgenetic alopecia, but advice and counselling remain the most important aspects of management

Eventually this island also disappears and only the marginal parietal and occipital hair remains. Ultimately the remaining hair thins and may also be lost.

In some men the loss over the vertex occurs more rapidly than the frontal loss; in others the entire frontal hairline marches back before a bald patch on the vertex develops. Less commonly, men bald in a Ludwig-type pattern,⁷ with preservation of their frontal hair line.

Most men are not aware of increased hair shedding and only notice that their hair is vanishing. Some men experience periods of increased and noticeable shedding.

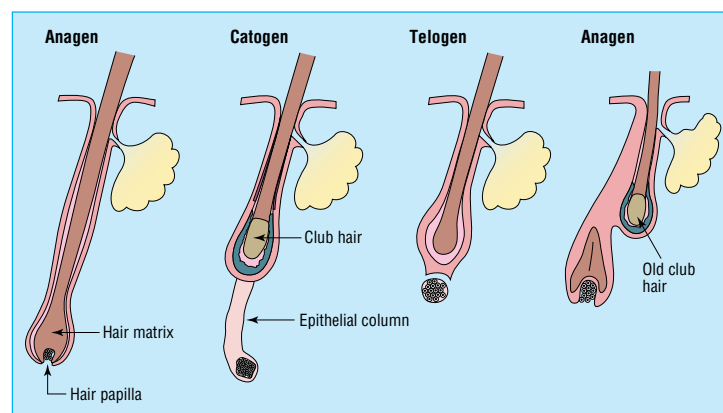
Hair loss usually does not start until after puberty, and the rate of progression is extremely variable. Some men go completely bald in less than 5 years but most take 15-25 years. One study found an average rate of hair loss of about 5% per year.⁸ Progression fluctuates considerably, with periods of accelerated loss lasting 3-6 months followed by quiescent periods lasting 6-18 months.

Histopathology

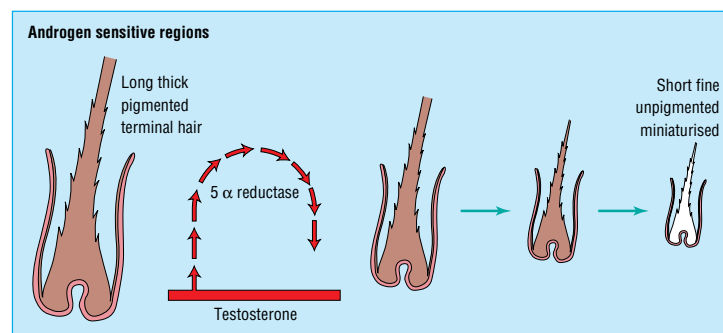
Routine vertical sectioned scalp biopsies show that terminal anagen hairs, which normally penetrate through

University of Melbourne, Department of Dermatology, St Vincent's Hospital, Victoria Parade, Melbourne 3065, Australia
Rodney Sinclair, senior lecturer
sinclair@svhm.org.au

BMJ 1998;317:865-9



Normal hair cycle



Stepwise miniaturisation of the hair follicle and shortening of the anagen growth phase, mediated by dihydrotestosterone

the dermis into the subcutis, are replaced by secondary vellus hairs with residual angiofibrotic tracts called follicular streamers or stellae.⁹ There seem to be fewer follicles, but the miniaturised follicles can be identified on horizontal sections of scalp biopsies. An additional feature is an increased ratio of telogen to anagen hairs.

A mild to moderately dense perifollicular lymphohistiocytic inflammatory infiltrate is seen around the infundibulum in up to two thirds of biopsies,⁹ but this is relatively non-specific as it is also seen in one third of normal controls.¹⁰

Pathogenesis

A model for the pathogenesis of androgenetic alopecia must account for the histological features mentioned above, in particular the miniaturisation of the hair follicle and an increase in the ratio of telogen to anagen hairs; the systemic and local effects of androgens in promoting the condition; and the familial tendency.⁴

Increased telogen hair count

The "hair loss" in androgenetic alopecia is the result of stepwise miniaturisation of the hair follicle and change in hair cycle dynamics.¹¹ The three phases of the normal hair cycle are shown in figure 1. During successive passages through the hair cycle the anagen phase becomes shorter and the telogen phase elongates, and the anagen to telogen ratio reduces from 12:1 to 5:1.¹⁰

The duration of anagen is the main determinant of hair length; as it decreases in successive cycles, the new anagen hair is shorter than its predecessor (fig 2). Ultimately anagen duration is so short the emerging hair

does not reach the skin surface and the only testimony to the presence of a functioning follicle is a pore.

As telogen hairs are more loosely anchored to the follicle than anagen hairs, the increased telogen count explains the increased hair shedding noticed during washing and combing the hair. In addition the latency period between telogen hair shedding and anagen regrowth becomes longer, leading to a reduction in the number of hairs present on the scalp.¹⁰

Follicular miniaturisation

The follicular miniaturisation that accompanies these hair cycle changes affects the papilla, the matrix, and ultimately the hair shaft. The dermal papilla is fundamental to the maintenance of hair growth¹² and is probably the target for androgen mediated changes in the hair cycle and miniaturisation of the follicle.¹³ With reduced follicle size, the hairs they produce become finer (mean diameter reduced from 0.08 mm to <0.06 mm), and pigment production decreases.⁸

Miniaturisation occurs in either early anagen or possibly catagen or telogen hairs, producing a stepwise reduction in size of the follicle with each successive cycle. The cross sectional area of individual hair shafts growing on the vertex of a balding scalp remains relatively constant throughout the late anagen phase.¹⁴ This explains the long time lag between the start of effective therapy and clinical response.

Systemic effects of androgens

Paradoxically the influence of androgens on hair is site specific. Prepubertal pubic, axillary, beard, and chest vellus hair follicles react to androgens by growing into terminal hairs. The same androgens miniaturise the pigmented terminal hairs on the scalp into non-pigmented vellus hairs.¹⁵ There is no satisfactory explanation for these different effects.

Studies in patients with androgen insensitivity syndromes¹⁶ and 5 α -reductase type 2 deficiency¹⁷ have suggested that androgenetic alopecia is induced by activation of follicular androgen receptors by dihydrotestosterone. Intrafollicular androgen overactivity may be due to local factors such as increased numbers of androgen receptors or increased local production of dihydrotestosterone, or to systemic factors such as increased circulating androgens providing increased substrate for conversion to dihydrotestosterone, or increased systemic production of dihydrotestosterone at distant sites such as the prostate gland.

5 α -Reductase catalyses the enzymatic conversion of testosterone to dihydrotestosterone, which binds to the same androgen receptor as the parent compound, but fivefold more avidly.⁵ Two isoenzymes of 5 α -reductase, types 1 and 2, are found in the scalp in adults. Nevertheless the amount of dihydrotestosterone produced by men in the scalp is small compared with that produced in the prostate. The relative contributions of locally and systemically produced dihydrotestosterone to the balding process has not yet been established.⁴

The degree of baldness is not correlated with the density of hair patterns on the trunk and limbs, nor with libido.¹⁸ This implies that the normal level of circulating testosterone after puberty is sufficient for maximal production of dihydrotestosterone.

Local effects of androgens

Loss of scalp hair occurs gradually over many years in an orderly and reproducible pattern and depends on factors within each follicle. Hair transplantation experiments show that occipital hairs maintain their resistance to androgenetic alopecia when transplanted to the vertex, and that scalp hairs from the vertex transplanted to the forearm miniaturise in synchrony with their original neighbours on the scalp.¹⁹ This tendency of transplanted hairs to maintain the characteristics of the donor site²⁰ is the basis of hair transplantation surgery.

The geographical patterning of the hair loss is associated with quantitative differences in numbers of androgen receptor²¹ and 5 α -reductase activity in balding and non-balding areas of the scalp. These events are most likely a secondary phenomenon as in vitro the follicle is able to regulate its own response to androgens by enhancing expression of 5 α -reductase and androgen receptors.^{21 22}

Inheritance of androgenetic alopecia

The genetics of androgenetic alopecia is complex. In general androgenetic alopecia is believed to be due to an autosomal dominant gene with variable penetrance, but a polygenic inheritance has not been excluded.²³

Candidate genes are those involved in androgen production and conversion of androgen to dihydrotestosterone. Analysis of candidate genes for androgenetic alopecia by restriction fragment length polymorphisms found no genetic variation in the 5 α -reductase type 1 gene or the 5 α -reductase type 2 gene or their regulation.²⁴

Adverse effects of androgenetic alopecia

Androgenetic alopecia is, for most men, an unwanted and stressful event that diminishes satisfaction with their body image. Only 8% of non-balding men stated that going bald would concern them, while 50% with mild hair loss and 75% with moderate to severe hair loss were concerned. They said it made them look older and less physically and sexually attractive than their non-balding peers.²⁵

Nevertheless, most men deal with their hair loss without it impairing their psychosocial functioning. The most distressed balding men are those with more extensive hair loss, those who are younger, have an earlier onset, and deem their balding as progressive (often arising from observation of their father) and socially noticeable. Men who are romantically unattached are also more likely to be distressed by balding.²⁵

Men outside these groups are more likely to seek treatment when they lack a strong, positive, body image. For such men any medical and surgical treatment should be complemented by measures to enhance self esteem.²⁶

Management of androgenetic alopecia

In general, people concerned about their androgenetic alopecia have four options. They can do nothing, get a wig, use medical treatment, or undergo surgery.

Without treatment, androgenetic alopecia is progressive. Nevertheless, for the vast majority of men,

doing nothing is the most appropriate option, and these people tend not to present to doctors. In addition many people seeking treatment will choose to do nothing when presented with their alternatives; supportive counselling and reassurance may help them come to terms with their hair loss.

Bogus treatments

The episodic nature of the hair loss has led many people to believe erroneously that a treatment or action chronologically associated with the cessation of hair shedding was causally related. This has led to the evolution of a large number of over the counter products that are promoted for hair loss. Although their ingredients are generally safe for external use, they do not promote hair growth or prevent hair loss.²⁷ In 1980 an advisory panel to the US Food and Drug Administration evaluated a number of substances used in hair lotions and creams—including amino acids, aminobenzoic acid, ascorbic acid, benzoic acid, B vitamins, hormones, jojoba oil, lanolin, polysorbates 20 and 660, sulphanilamide, tetracaine hydrochloride, urea, and wheat germ oil—and subsequently proposed that these products be removed from the market.²⁸ Other ineffective remedies include scalp massage, dietary modification, frequent shampooing, electrical stimulation, and Chinese herbal extracts.²⁷

Wigs

Many men prefer wigs to scalp surgery. Wigs can either be interwoven with existing hair or worn over the top of existing hair. Interwoven wigs tend to lift as the hair beneath grows and require adjustment every few weeks; this may add considerably to the expense.

Medical treatment

Currently there are two treatments approved by the Food and Drug Administration in the United States for the treatment of androgenetic alopecia in men: topical minoxidil and oral finasteride. The androgen receptor antagonists used to treat women are not suitable for men because of the potential risks of gynaecomastia, feminisation, and impotence.

Topical minoxidil

The 2% minoxidil solution is available over the counter in Britain, but a prescription is required for the 5% concentration. Hypertrichosis was noted as a side effect in men treated for hypertension with oral minoxidil. This led to the development of a topical formulation that was purported to arrest progression of the hair loss and regrow hair in about 90% of men; 60% had a medium to dense regrowth of hair.²⁹ The large placebo response seen in this and other trials indicated that techniques used to evaluate the hair growth were far from perfect. In my experience these figures overestimate the benefit of minoxidil and only about 15% receive medium regrowth while 50% have their hair loss delayed and 35% continue to lose hair. Dense regrowth is exceptional. Much of the regrowth is of cosmetically insignificant indeterminate hairs rather than true terminal hairs, and the primary benefit is to halt progression of the balding. On stopping treatment all these new hairs are shed³⁰ (table). Oral minoxidil provides no added benefit over topical minoxidil, and in view of its potential side effects, it should not be

Hair loss and regrowth with minoxidil and finasteride. Values are percentages

Results of treatment	Minoxidil at 12 months	Finasteride	
		12 months	24 months
Growth/loss of hair:			
Regrowth	15	48	66
No progression of loss	50	51	33
Progression of hair loss	35	1	1
Outcome on cessation			
	Loss of all regrown hair within 3 months	Regrown hair persists but the balding process resumes	

used. The combination of topical minoxidil with topical tretinoin is limited by irritation of the scalp, and the benefits have not been substantiated in large studies. Topical inoxidil has few side effects: skin irritation and, rarely, contact allergic dermatitis.

Oral finasteride

Finasteride, a potent 5 α -reductase type 2 inhibitor,³¹ received approval from the Food and Drug Administration for treating androgenetic alopecia in men in December 1997. In the first phase 3 study, 933 men aged 18 to 41 with mild to moderate androgenetic alopecia hair loss were randomised to receive either finasteride 1 mg/day or placebo for one year. Photographs evaluated by a blinded panel of dermatologists showed that in 1% of men the hair loss progressed, in 51% the hair loss stabilised, and in 48% hair regrew (table). Hair regrowth was graded as slight in 30%, moderate in 16% and greatly increased in 2%. A similar analysis after 24 months in 508 patients showed a greater response, with 32% having moderately or greatly increased hair, 34% of patients having minimal regrowth, and the remainder stabilising (D Whiting, personal communication).

A response to finasteride may be seen after 4 months, but patients should be encouraged to continue the treatment for at least 24 months before evaluating it. If successful, the treatment should be continued indefinitely as the balding process continues when treatments stopped. The rapid hair fall seen with stopping minoxidil does not occur with finasteride (D Whiting, personal communication).

The incidence of side effects in the finasteride group was similar to placebo, and the only important side effect was loss of libido in 1.8% of men receiving finasteride versus 1.3% on placebo. This returned to normal in all cases in which the drug was stopped and in many cases with continued treatment.

An 0.05% formulation of topical finasteride was well absorbed and lowered the serum dihydrotestosterone concentration by up to 40% but did not regrow hair.³² This suggests that the main action of finasteride is to lower circulating dihydrotestosterone through inhibiting production by the prostate, rather than affecting the metabolism of androgen in the hair follicle.

Scalp surgery

Excision of bald scalp with or without tissue expansion, scalp flaps, and hair transplantation have been used to treat advanced androgenetic alopecia for some years and are constantly undergoing revision and improvement. These have all been recently reviewed.³³ While artificial fibre implantation has been used for androgenetic alopecia when donor fibres are unavailable, great caution is advised as foreign body reactions and infections are potentially serious complications.³⁴

Future developments

Second generation steroidal 5 α -reductase inhibitors such as turosteride, MK-963, MK-434, episteride, and MK-386, some of which also inhibit the type 1 isoenzyme, have been developed and are undergoing further investigation, as are a variety of non-steroidal inhibitors such as zinc.³⁵

The possibility of gene therapy for androgenetic alopecia has been advanced by the development of a topical cream containing liposomes to deliver entrapped DNA selectively to hair follicles in mice.³⁶ Though the development of a cream that could permanently restrict androgen receptor expression within the hair follicle is many years away, research is focusing in that direction.

Conclusions

The important advances in the field of androgenetic alopecia include the development of hair culture systems to investigate the pathogenesis of androgenetic alopecia and specific antagonist drugs; the increased understanding of hair cycle dynamics with the description of the latent phase in the hair cycle; and the development of finasteride (currently only available in the United States), which promises to be an effective treatment.

All of the currently available treatments are suppressive and not curative. Supporting the patients emotionally and ensuring they understand the limitations of these treatments remains one of the most important components of the management of androgenetic alopecia.

Funding: None.

Conflict of interest: None.

- Randall VA. Androgens and human hair growth. *Clin Endocrinol* 1994;40:439-57.
- Hamilton JB. Male hormone stimulation is a prerequisite and an incitant in common baldness. *Am J Anat* 1942;71:451-80.
- Hamilton JB. Effect of castration in adolescent and young adult males upon further changes in the proportion of bare and hairy scalp. *J Clin Endocrinol Metab* 1960;20:1309-18.
- Simpson NB, Barth JH. Hair patterns: hirsutes and androgenetic alopecia. In: Dawber RPR, ed. *Diseases of the hair and scalp*. Oxford: Blackwell Science, 1997.
- Hamilton JB. Male pattern hair loss in man: types and incidence. *Ann N Y Acad Sci* 1951;53:708-28.
- Sety LR. Hair patterns of the scalp of white and Negro males. *Am J Phys Anthropol* 1970;33:49-55.
- Kuhlwein A. Androgene Alopecie vom weiblichen Typ beim Mann. *Z Hautkr* 1985;60:576-578.
- Rushon DH, Ramsay ID, Norris MJ, Gilkes JJ. Natural progression of male pattern baldness in young men. *Clin Exp Dermatol* 1991;16:188-92.
- Kligman AM. The comparative histopathology of male pattern baldness and senescent baldness. *Clin Dermatol* 1988;6:108-18.
- Whiting D. Diagnostic and predictive value of horizontal sections of scalp biopsy specimens in male pattern androgenetic alopecia. *J Am Acad Dermatol* 1993;28:755-63.
- Curtois M, Loussouarn G, Horseau C, Grollier JF. Hair cycle and alopecia. *Skin Pharmacol* 1994;7:84-9.
- Oliver RF, Jahoda CAB. The dermal papilla and the maintenance of hair growth. In: Rogers GA, Reis PR, Ward KA, Marshall RC, eds. *The biology of wool and hair*. London: Chapman and Hall, 1989:51-67.
- Obana NJ, Uno H. Dermal papilla cells in macaque alopecia trigger a testosterone-dependent inhibition of follicular cell proliferation. In: van Neste D, Randall VA, eds. *Hair research in the next millennium*. Amsterdam: Elsevier, 1996:307-10.
- Hutchinson PE, Thompson JR. The cross-sectional size and shape of human terminal scalp hair. *Br J Dermatol* 1997;136:159-65.
- Kaufman KD. Androgen metabolism as it affects hair growth in androgenetic alopecia. *Dermatol Clin* 1996;14:697-711.
- Griffin JE, Wilson JD. The resistance syndromes: 5 α reductase deficiency, testicular feminisation and related disorders 1989. In: Baudet AI, Sly WS, Valle D, eds. *The metabolic basis of inherited disease*. New York: McGraw-Hill, 1989:1919-44.
- Imperato-McGinley J, Guerrero L, Gautier T, Peterson RE. Steroid 5 α reductase deficiency in man: an inherited form of male pseudohermaphroditism. *Science* 1974;186:1213-5.

- 18 Burton JL, Halim MM, Meyrick G, Jeans WD, Murphy D. Male pattern alopecia and masculinity. *Br J Dermatol* 1979;100:567-71.
- 19 Norstrom RE. Synchronous balding of scalp and hair bearing grafts of scalp transplanted to the skin of the arm in male pattern baldness. *Acta Derm Venereol* 1979;59:266-8.
- 20 Orentreich N. Autografts in alopecia and other selected dermatological conditions. *Ann NY Acad Sci* 1959;83:462.
- 21 Randall VA, Thornton MJ, Messenger AG. Cultured dermal papilla cells from androgen-dependent human hair follicles (eg beard) contain more androgen receptors than those from non-balding areas of the scalp. *J Endocrinol* 1992;133:141-7.
- 22 Itami S, Kurata S, Takayasu S. 5 α reductase activity in cultured dermal papilla cells from beard compared with reticular dermal fibroblasts. *J Invest Dermatol* 1990;94:150-2.
- 23 Kuster W, Happle R. The inheritance of common baldness: two B or not two B? *J Am Acad Dermatol* 1984;11:921-6.
- 24 Ellis JA, Stebbing M, Harrap SB. Genetic analysis of male pattern baldness and 5 α reductase genes. *J Invest Dermatol* 1998;110:849-53.
- 25 Cash TF. The psychological effects of androgenetic alopecia in men. *J Am Acad Dermatol* 1992;26:926-31.
- 26 Cash TF, Butters JW. Poor body image: helping the patient to change. *Med Aspects Hum Sexuality* 1988; 22:67-70.
- 27 Orentreich D, and Orentreich N. Androgenetic alopecia and its treatment, a historical view. In: Unger WP, ed. *Hair transplantation*. 3rd ed. New York: Marcel Dekker, 1995:1-33.
- 28 Hecht A. Hair grower and hair-loss prevention drugs. *FDA Consumer*, 1985 April 19:1-3.
- 29 Savin RC. Use of topical minoxidil in the treatment of male pattern baldness. *J Am Acad Dermatol* 1987;16:696-704.
- 30 Olsen EA, Weiner MS. Topical minoxidil in male pattern baldness: effects of discontinuation of treatment. *J Am Acad Dermatol* 1987;17:97-101.
- 31 Olsen E. Finasteride (1 mg) in the treatment of androgenetic alopecia in men [abstract]. *Aust J Dermatol* 1997;38:A316.
- 32 Rushton DH, Norris MJ, Ramsay ID. Topical 0.05% finasteride significantly reduced serum DHT concentrations, but had no effect in preventing the expression of genetic hair loss in men. In: Van Neste D, Randall VA, eds. *Hair research for the next millennium*. Amsterdam: Elsevier, 1996:359-62.
- 33 Unger WP. Surgical approach to hair loss. In: Olsen EA, ed. *Disorders of hair growth. Diagnosis and treatment*. New York: McGraw-Hill, 1994:353-74.
- 34 Lepaw MI. Complications of implantation of synthetic fibres into scalps for 'hair' replacement: experience with fourteen cases. *J Dermatol Surg Oncol* 1979;5:201-4.
- 35 Chen W, Zouboulis CC, Orfanos CA. The 5 α reductase system and its inhibitors. Recent development and its perspective in treating androgen dependent skin disorders. *Dermatol* 1996;193:177-84.
- 36 Li L, Hoffman RM. The feasibility of targeted selective gene therapy of the hair follicle. *Nature Med* 1995;1:705-6.

(Accepted 12 February 1998)

Lesson of the week

Treatment resistant epilepsy or convulsive syncope?

Amir Zaidi, Peter Clough, Bruce Scheepers, Adam Fitzpatrick

The diagnosis of epilepsy is complicated by various conditions that can mimic an epileptic seizure, and cardiovascular conditions causing syncope may account for many cases of so called secondary seizures.¹ Convulsive syncope—that is, cerebral anoxic seizure activity secondary to transient global impairment of blood flow—can be difficult to differentiate from epilepsy. The differentiation is, however, important because syncope can be treated effectively, especially when it is due to a bradycardia.¹ In addition, long term anticonvulsant treatment is expensive and can cause serious morbidity.² We present the cases of three patients thought to have treatment resistant epilepsy who were subsequently found to have a cardiac condition.

Case histories

Case 1

A 32 year old woman was referred to the epilepsy clinic in January 1995 with a four year history of recurrent blackouts. She described episodes in which she became weak and had to lie on the floor followed by loss of consciousness lasting for about 1 minute with clenching of her fist and sometimes jerking, especially of the legs, but no incontinence or tongue biting. She normally recovered quickly, although she was tired afterwards. The episodes occurred up to four times a week. In 1991, a 72 hour electroencephalogram had given normal results, but a trace taken after sleep deprivation showed some left sided slow wave changes. She was started on phenytoin for presumed epilepsy. She subsequently tried several anticonvulsant drugs including lamotrigine, sodium valproate, clobazam, vigabatrin, carbamazepine, and gabapentin with no significant improvement apart from a short period when clobazam was introduced. Her condition had deteriorated with gabapentin.

At referral she was taking clobazam, vigabatrin, and carbamazepine. She was changed to carbamazepine

only (800 mg daily) with little effect on the frequency of attacks. Repeat ambulatory electroencephalography and magnetic resonance imaging of the brain gave normal results. She was admitted to the David Lewis Centre in November 1996 for assessment. She had a typical attack during ambulatory electroencephalographic monitoring. Immediately before the attack a sinus pause of about 5 seconds was recorded on her electrocardiogram, and she was transferred to a coronary care unit for further assessment. Electrocardiographic monitoring showed frequent sinus pauses lasting up to 7 seconds. A dual chamber permanent pacemaker was implanted and her blackouts resolved completely.

Case 2

A 43 year old man was referred for a neurological opinion in 1991 with a six year history of recurrent funny turns. He developed buzzing in his right ear followed by severe dizziness but no loss of consciousness. Thorough investigations at his local hospital had produced no clear diagnosis. Electroencephalography and computed tomography of the brain showed no abnormality. In February 1992 he had an attack complicated by loss of consciousness and a convulsion. Epilepsy was diagnosed, and he was started on carbamazepine. However, he continued to have blackouts about every three months despite plasma anticonvulsant concentrations within the therapeutic range. He was referred to the Manchester Heart Centre in September 1992. Electrocardiography, echocardiography, and 24 hour Holter monitoring and carotid sinus massage gave normal results but he remained under yearly review. He had a tilt test³ in October 1995 after a cluster of blackouts. After 32 minutes of 60° head up tilt he developed a sudden nodal bradycardia of 20 beats/minute with syncope in keeping with a diagnosis of vasovagal syncope.⁴ He had a dual chamber pacemaker inserted in April 1996 and anticonvul-

A primary cardiac problem should always be considered in patients with apparent epilepsy who respond poorly to treatment

Manchester Heart Centre, Royal Infirmary, Manchester M13 9WL
Amir Zaidi, research fellow
Adam Fitzpatrick, consultant cardiologist

David Lewis Centre for Epilepsy, Warford, Alderley Edge, Cheshire SK9 7UD

Peter Clough, clinical medical officer
Bruce Scheepers, consultant neuropsychiatrist

Correspondence to: Dr Zaidi amir@mhc.cmht.nwest.nhs.uk

BMJ 1998;317:869-70