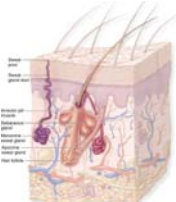


**Androgenetic Alopecia: New insights into the role of the Arrector Pili Muscle**

Rodney Sinclair  
 MBBS, MD, FACD




---

---

---

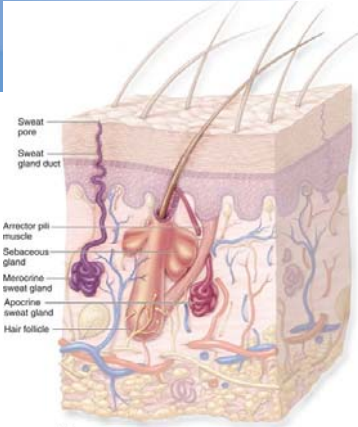
---



---

---

---

---



---

---

---

---

---

---

---

---




**Beard**



**Forearm**




---

---

---

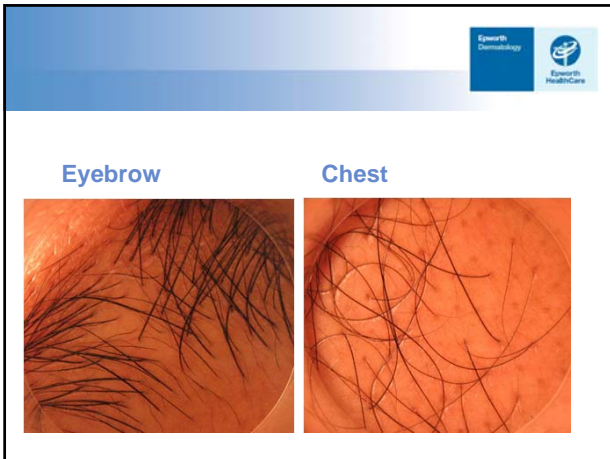
---

---

---

---

---




---

---

---

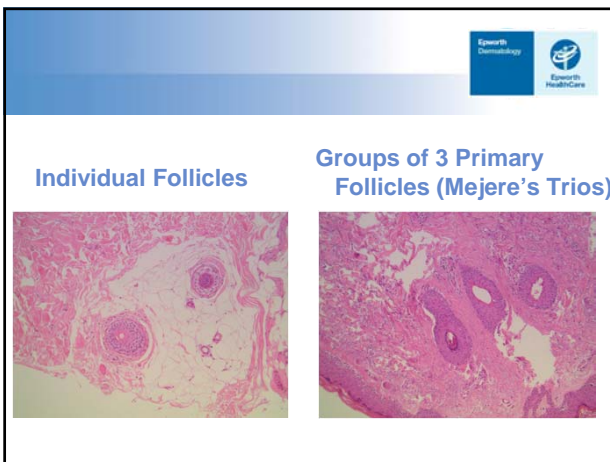
---

---

---

---

---




---

---

---

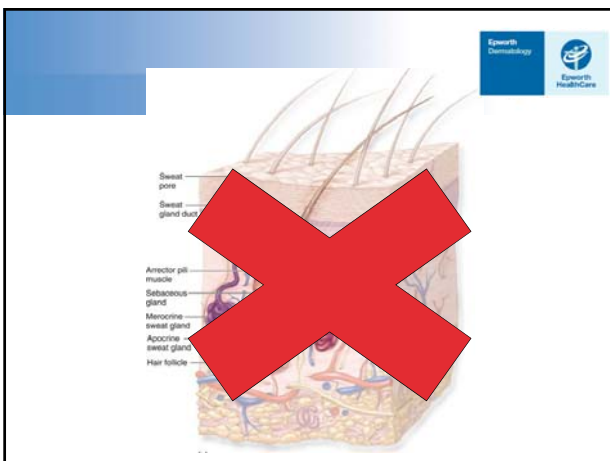
---

---

---

---

---




---

---

---

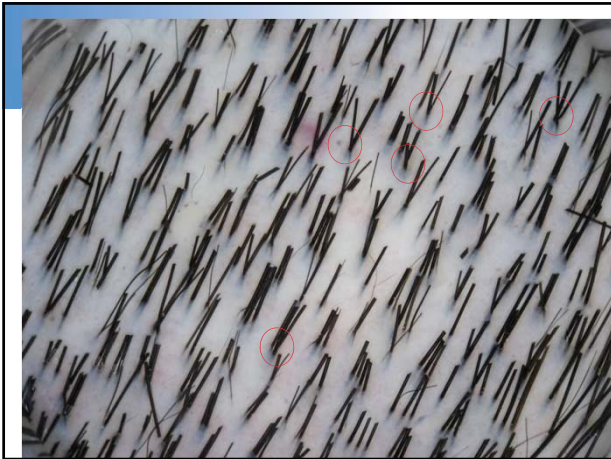
---

---

---

---

---




---

---

---

---

---

---

---

---

**Follicular Units**

Epworth Dermatology Epworth HealthCare

Arrector pili  
Vellus hair  
Sebaceous gland  
Terminal hair

---

---

---

---

---

---

---

---

**Common Clinical Scenario**

35 year old woman presents with increased hair shedding, a reduction in the thickness of her pony tail by a third but apparently normal hair density over mid frontal scalp.

Scalp biopsy shows androgenetic alopecia with a terminal to vellus hair ratio of 2:1

Epworth Dermatology Epworth HealthCare

---

---

---

---

---


---

---

---

Diffuse Thinning precedes Baldness in women

Yazdabadi A, Magee J, Harrison S, Sinclair R.  
**The Ludwig pattern of androgenetic alopecia is due to a hierarchy of androgen sensitivity within follicular units that leads to selective miniaturization and a reduction in the number of terminal hairs per follicular unit.**  
Br J Dermatol. 2008



Stage 1      Stage 2      Stage 3      Stage 4      Stage 5

---

---

---

---

---

---

---

---

---

---

Diffuse hair loss in women is due to a reduction in the number of hairs per follicular unit rather than uniform miniaturization of entire follicular units

---

---

---

---

---

---

---

---

---

---



---

---

---

---

---

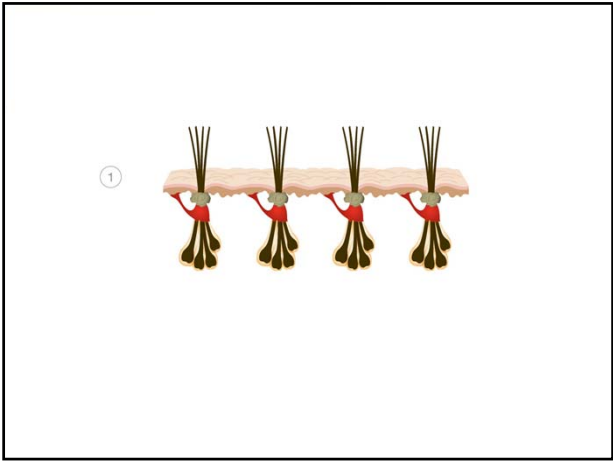
---

---

---

---

---



---

---

---


---

---

---

---

---



---

---

---


---

---

---

---

---



---

---

---


---

---

---

---

---



---

---

---

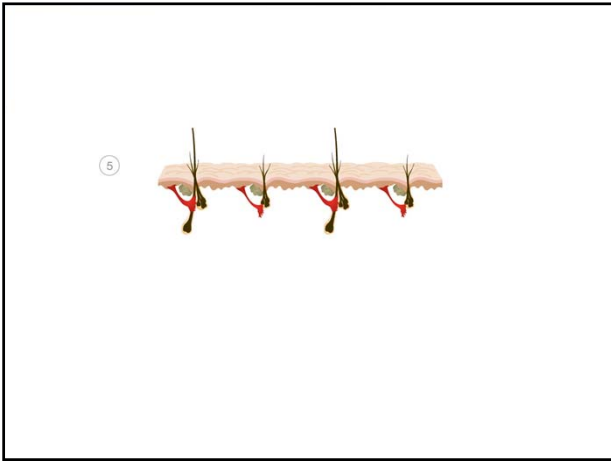
---

---

---

---

---



---

---

---


---

---

---

---

---



---

---

---

---

---

---

---

---

Summary



New model for early AGA

- Hair growth on the scalp is different to the rest of the body
- There is a hierarchy in follicular units with primary and secondary hairs
- Secondary hairs arise in utero from a stem cell population below sebaceous gland but above bulge
- Secondary hairs miniaturize first in AGA
- Reduction in the number of hairs emerging from each pore is a sign of early AGA

---

---

---

---

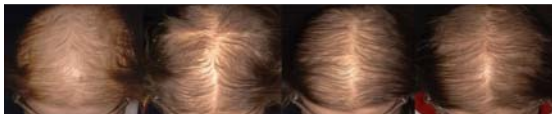---

---

---

---

Patient 102-Androcur 100mg for 10 days per month



Baseline      6 months      12 months      24 months

---

---

---

---

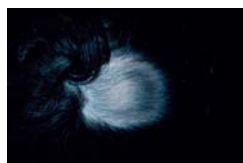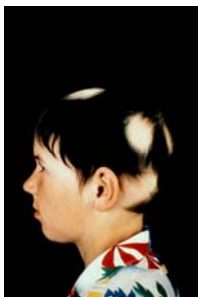---

---

---

---

Another clinical scenario



Intralosomal corticosteroids

---

---

---

---

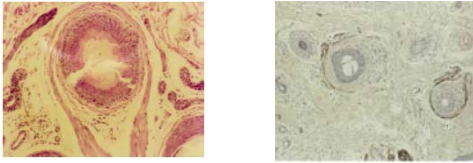
---

---

---

---

- Arrector pili muscle surrounds human facial vellus hair follicles



---

---

---

---

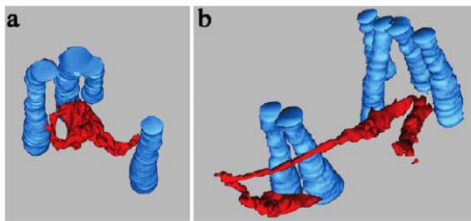
---

---

---

---

Arrector pili muscle



---

---

---

---

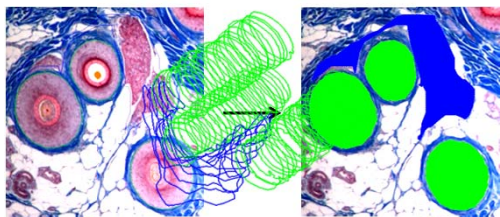
---

---

---

---

Method



---

---

---

---

---

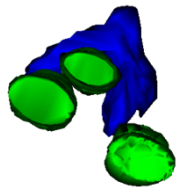
---

---

---



Diffuse Alopecia



---

---

---

---

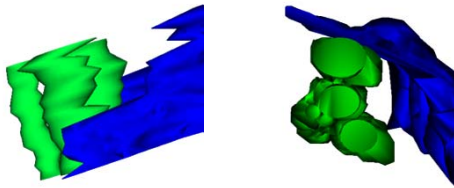
---

---

---

---

Female Pattern Hair Loss



---

---

---

---

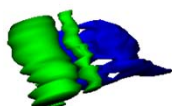
---

---

---

---

Male Pattern Hair Loss



---

---

---

---


---

---

---

---

Alopecia Areata



Epworth Dermatology Epworth HealthCare

---

---

---

---

---

---

---

---

International Journal of Trichology

Miniaturized hairs maintain contact with the arrector pili muscle in alopecia areata but not in androgenetic alopecia: A model for reversible miniaturization and potential for hair regrowth

Anousha Yazdabadi<sup>1</sup>, D Whiting<sup>2</sup>, NW Rufaut<sup>1</sup>, R Sinclair<sup>1</sup>,  
Int J Trichol 2012;4:154-157

Epworth Dermatology Epworth HealthCare

---

---

---


---

---

---

---

---



Epworth Dermatology Epworth HealthCare

---

---

---


---

---

---

---

---



---

---

---


---

---

---

---

---



---

---

---


---

---

---

---

---



---

---

---


---

---

---

---

---



---

---

---


---

---

---

---

---



---

---

---

---

---

---

---

---



---

---

---


---

---

---

---

---



---

---

---

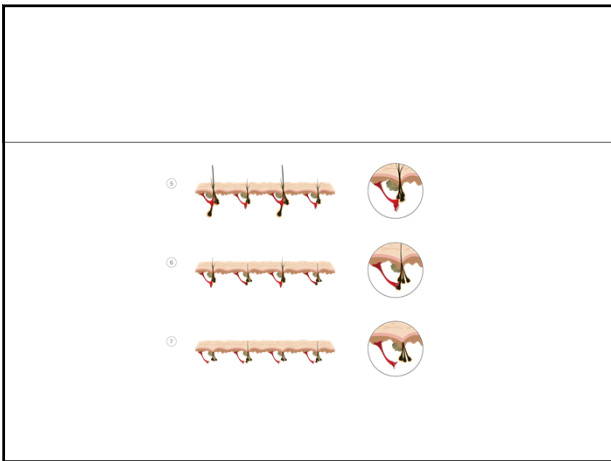
---

---

---

---

---



---

---

---

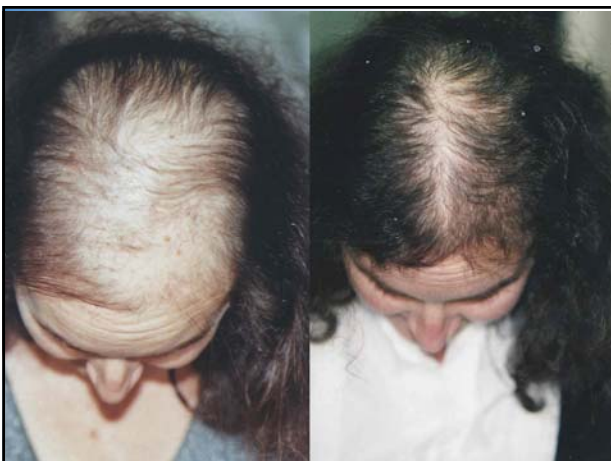---

---

---

---

---



---

---

---

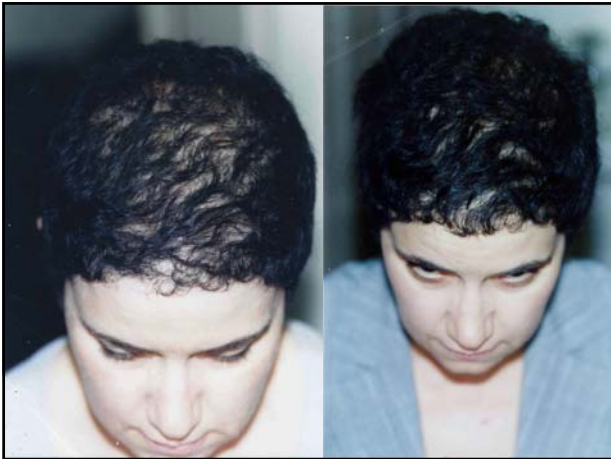---

---

---

---

---



---

---

---

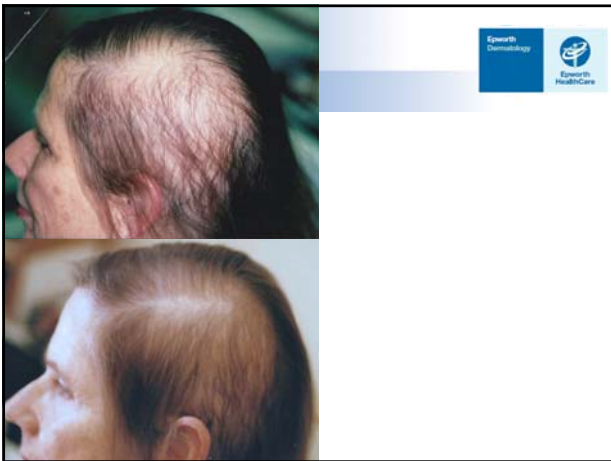
---

---

---

---

---



---

---

---

---

---

---

---

---

Summary

- Oral Minoxidil at doses of 1mg daily appears well tolerated from the cardiovascular point of view
- Concomitant use of spironolactone minimises the development of peripheral oedema and weight gain and probably has a synergistic effect
- Hypertrichosis may occur in up to 30% of patients but is generally mild, well tolerated and responds to dose reduction

---

---

---

---

---

---

---

---

## Side effects



- Not observed at dose of 1 mg/d minoxidil
- Fluid retention not seen in any man
- No postural dizziness or palpitations
- No patient discontinued treatment

---

---

---

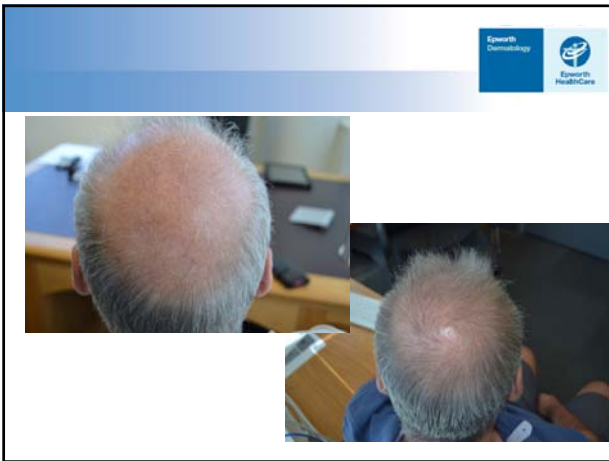---

---

---

---

---



---

---

---


---

---

---

---

---



---

---

---


---

---

---

---

---



---

---

---

---

---

---

---

---

Summary

- Low dose oral minoxidil appears promising as a hair growth promoter
- Patients should be counselled re initial transient shedding reflecting postulated mechanism of action for the drug
- Allows dose reduction of finasteride with fewer adverse sexual side effects

---

---

---

---

---

---

---

---