

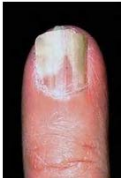Nails

Examination and Disorders

Samantha Eisman

Dermatologist

MBChB/ MRCP/ FCDerm(SA)/ FACD



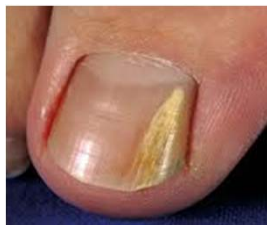Overview

- Demystify nails
- QUIZ
- Talk
 - Examination nails and site specific disease
- QUIZ
 - answers and cover common nails disease
- MCQ



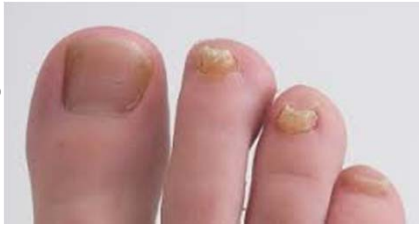Case 1

- 25 year old woman
- Noticed at pedicure
- Single toe
- What is diagnosis?
- How would you diagnose?
- How would you treat?

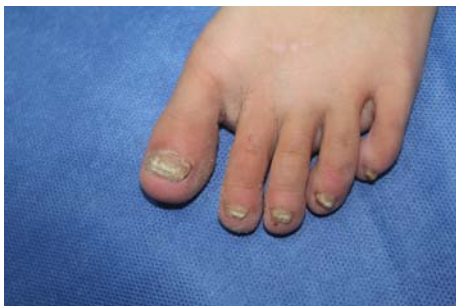

Case 2

- 12 year old girl
- 4 nails
- Diagnosis?
- Treatment?
- Concerns?



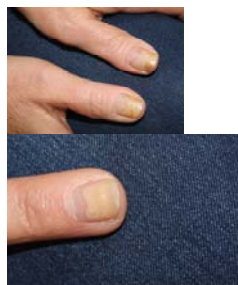
Case 3 8 year old twin



4 year history of nail problem left foot only. No help numerous topicals. Twin sister no nail issues. Family history psoriasis. Fungal- mycotic elements only

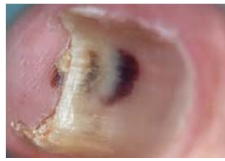Case 4

- 50 year female
- nail problem months
- sister has nails problems
- skin NAD
- GP- negative nail clippings
- Terbinafine for 1 year



- Diagnosis/Differential Diagnosis?
- Thought re terbinafine choice and length treatment?

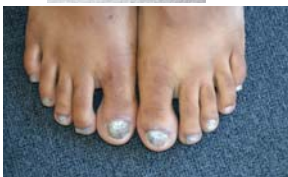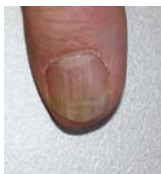Case 5



- 42 year old from South America
- No response to loceryl 6 months

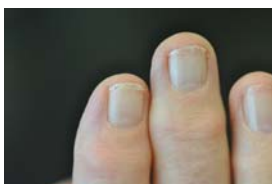- Diagnosis?
- Differential?
- Management?

Case 6



- What clinical signs are evident?
- What is the differential?
- What other skin manifestations may be present?
- What other nail changes can be present with this condition?

Case 7

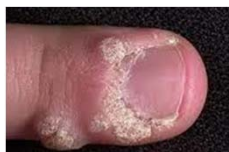

- 50 year old lady
- Housewife
- Concern re 'weak' nails
- Medically well

- Diagnosis?
- Treatment?
- Preventions?

Case 8

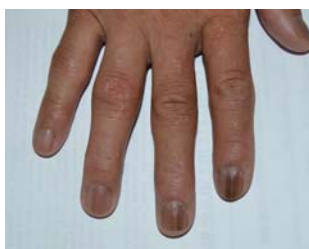- 10 year old boy
- Teased at school
- Tried OTC products



- Diagnosis?
- Management options?
- Concerns?

Case 9

55 year old woman
Few years hx of nail changes



What is the diagnosis?
Would the prognosis be different if one nail was affected?

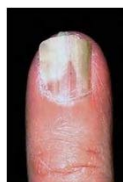Nails

Examination and Disorders

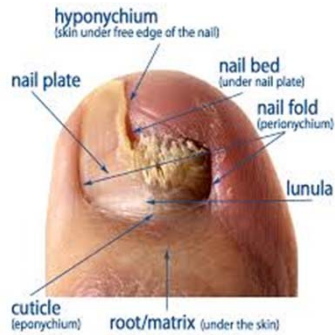
Samantha Eisman

Dermatologist

MBChB/ MRCP/ FCDerm(SA)/ FADC

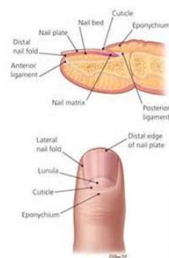


Nail Examination and site specific diseases of the nail



Sites of nail disease

- 1.Nail plate
- 2.Nail colour
- 3.Nail fold and cuticle
- 4.Nail shape
- 5.Lesions around the nail



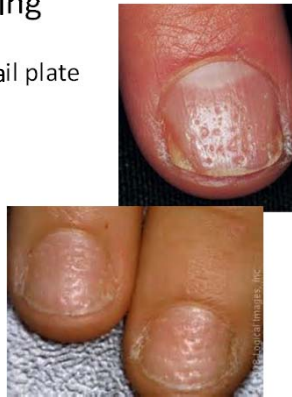1.Nail plate

- **Pitting**
- Ridging
- Thickening (onychogryphosis)
- Crumbling
- Splitting
- Rough (trachyonychia)

Pitting

- Punctate depression nail plate
- Damage to matrix

- Psoriasis
- Alopecia areata
- Eczema

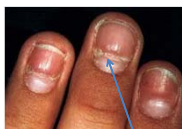

1.Nail plate

- Pitting
- **Ridging**
- Thickening (onychogryphosis)
- Crumbling
- Splitting
- Rough (trachyonychia)

Ridging

- Transverse

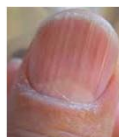
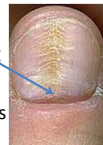
- Beau's lines
- Eczema
- Psoriasis
- Paronychia



- Longitudinal

- Habit picking
- Aging
- Lichen planus
- Psoriasis
- Fungal

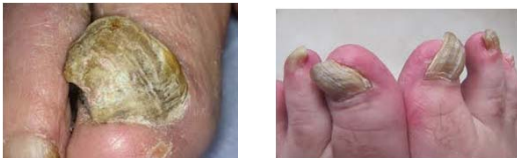

1.Nail plate

- Pitting
- Ridging
- **Thickening (onychogryphosis)**
- Crumbling
- Splitting
- Rough (trachyonychia)

Thickening

- Rams horn nails
- Elderly/ Psoriasis/ Trauma

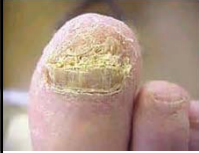

1.Nail plate

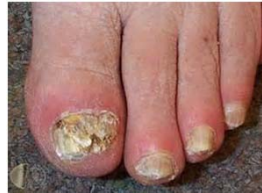- Pitting
- Ridging
- Thickening (onychogryphosis)
- **Crumbling**
- Splitting
- Rough (trachyonychia)

Crumbling

- Tinea



- Psoriasis

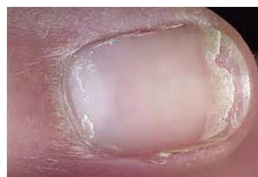
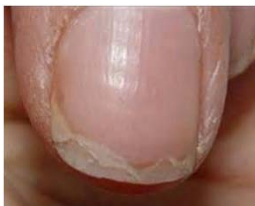
1.Nail plate

- Pitting
- Ridging
- Thickening (onychogryphosis)
- Crumbling
- **Splitting**
- Rough (trachyonychia)

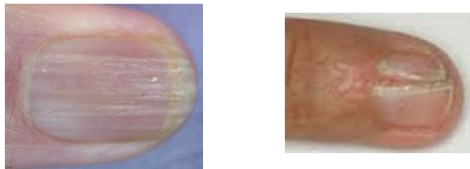
Splitting: Distal

- = lamellar onychoschizia
- Distal edge
- Repeated soaking in water/ detergent



Splitting: Longitudinal

- Extension of ridging
- Psoriasis/ Fungal/ Lichen Planus

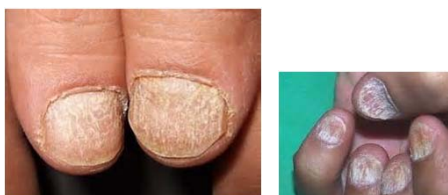

1.Nail plate

- Pitting
- Ridging
- Thickening (onychogryphosis)
- Crumbling
- Splitting
- Rough (trachyonychia)

Rough

- Sandpapered nails
- 20 Nail dystrophy
- Psoriasis/ Lichen Planus/ Alopecia Areata



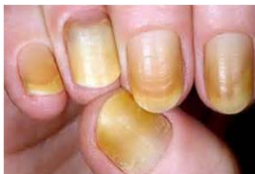2.Nail Colour

- Yellow
- Green
- White
- Purple/Black
- Streaks

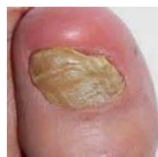Yellow

Yellow Nail Syndrome

- Yellow/ green
- Hard
- Elevated longitudinal curve
- Loss cuticle/ pain/ shed
- Associated medical disease



Fungal/ Psoriasis

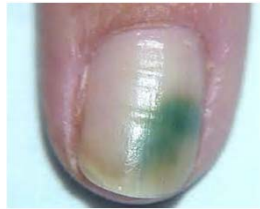

2.Nail Colour

- Yellow
- Green
- White
- Purple/Black
- Streaks

Green

- Green Nail Syndrome: Pseudomonas



- Keep nail short
- Vinegar soaks

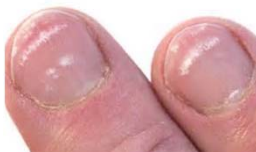2.Nail Colour

- Yellow
- Green
- White
- Purple/Black
- Streaks

White

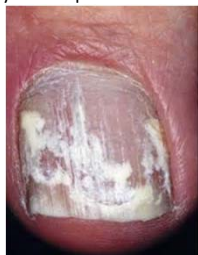1.Trauma

- manicuring



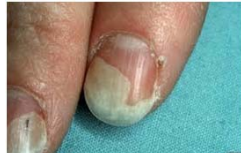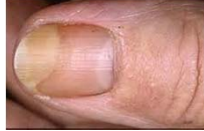2. Superficial White Onychomycosis

- chalky white spots



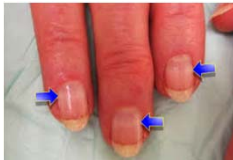3. Onycholysis

- Distal nail plate detached
- Detached nail white/ yellow
- Causes
 - Skin disease (PSO)
 - Infections (Fungal/ candida)
 - Metabolic (hyperTH)
 - Environment (trauma/ UV)
 - Drugs (tetracyclines)
 - Tumours



4. Other

- Chronic renal failure/ Low albumin/ Cirrhosis
- Familial
- Arsenic

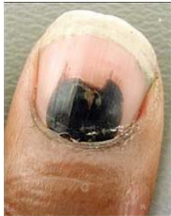
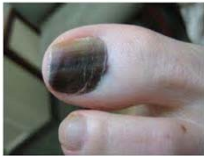
2.Nail Colour

- Yellow
- Green
- White
- Purple/Black
- Streaks

Purple/ Black

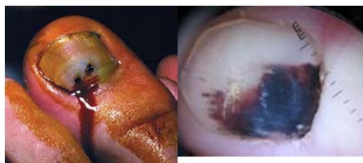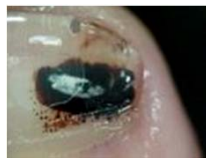
- Melanoma
- Haematoma



- Blood under nail plate
- Move distally with growth
- Painful

Haematoma

- Dermoscopy
 - Blood spots
 - Proximal round edge
 - Distal linear and parallel
- Treatment
 - Drain if painful
 - Refer

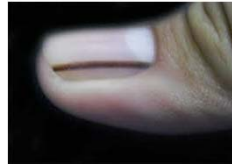
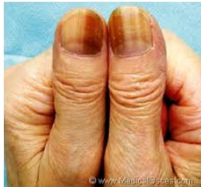
2.Nail Colour

- Yellow
- Green
- White
- Purple/Black
- Streaks

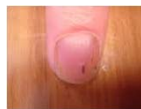Streaks

- Longitudinal melanonychia
 - Familial/ trauma/ drugs/ Pregnancy/ HIV/ genetic
 - Matrix naevus
 - Melanoma

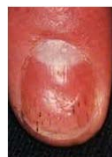

Splinter Haemorrhages

- Longitudinal dark-red lines- distal nail
- Damage to nail bed capillaries
- Causes
 - Traumatic
 - Psoriasis
 - Fungal
 - Endocarditis (SBE)



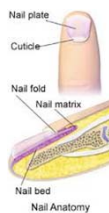SBE



psoriasis

3. Nail Fold and Cuticle

- **Cuticle**
- Subungual hyperkeratosis
- Paronychia
- Ingrown nail



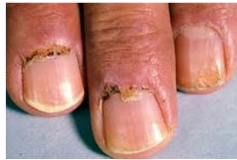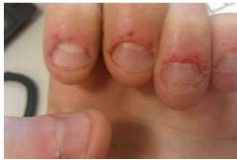Cuticle

Traumatic

- Biting

Ragged/ Telangiectasia

- Connective tissue

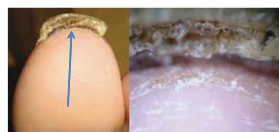
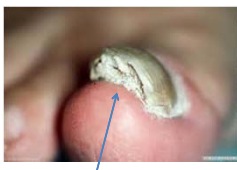
3. Nail Fold and Cuticle

- Cuticle
- Subungual hyperkeratosis
- Paronychia
- Ingrown nail

Subungual Hyperkeratosis

- Scale under hyponychium
- Psoriasis/ Fungal/ Crusted scabies

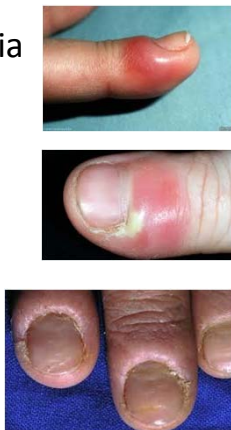

3. Nail Fold and Cuticle

- Cuticle
- Subungual hyperkeratosis
- Paronychia
- Ingrown nail

Paronychia

- Acute
 - swollen, red, pain
 - Staph/ strep/ HSV
 - Minor trauma
 - Antibiotic +/- surgery
- Chronic
 - Inflamed proximal nail fold
 - No cuticle
 - Nail plate abnormality
 - More than one finger
 - 2^o infection
 - Avoid water

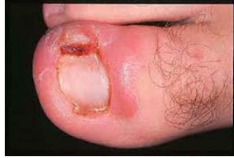
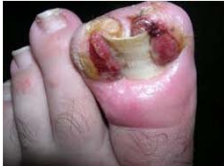
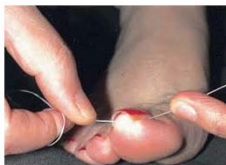3. Nail Fold and Cuticle

- Cuticle
- Subungual hyperkeratosis
- Paronychia
- Ingrown nail

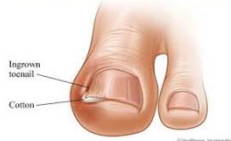Ingrown Nail

- Nail plate spicule into lateral nail fold
- Painful
- Improper cutting of nail





- Treatment
 - Educate
 - Remove spicule: floss/ cotton
 - Destruction lateral matrix: chemical/ surgery

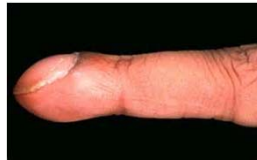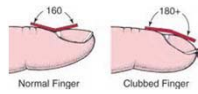


4. Nail Shape

- Clubbing
- Koilonychia
- Others

Clubbing

- Bulbous digits
- Congenital
 - CHD/ CF
- Acquired
 - Lung: ca lung/ PTB
 - CVS: SBE
 - GIT: IBD/ Liver
 - Infection: HIV
 - Endocrine: hyperTH

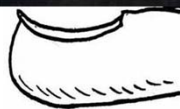
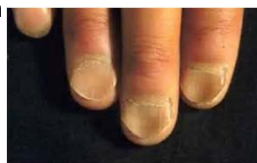
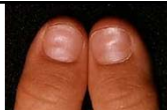4. Nail Shape

- Clubbing
- Koilonychia
- Others

Koilonychia

- Nail plate thin/ flat/ spoon
- Normal in children
- Adults: iron deficiency



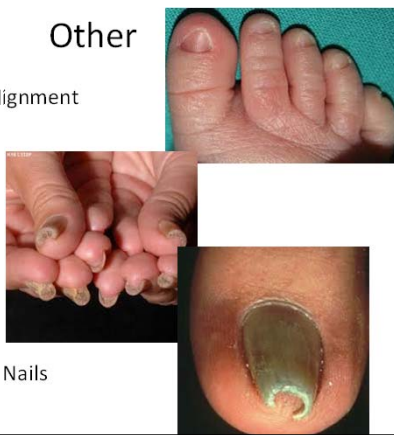Spoon nail

4. Nail Shape

- Clubbing
- Koilonychia
- Others

Other

- Congenital malalignment
- Pachyonychia
- Pincer/ Trumpet Nails

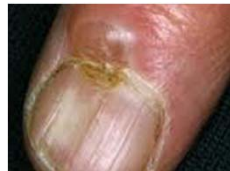
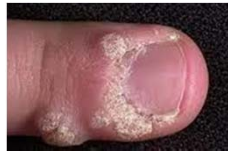
5. Lesions around the nail

- Benign
 - Warts
 - Fibroma
 - Myxoid cyst
 - Corn/callus
- Malignant
 - Melanoma
 - SCC
 - Bowens

Benign

- Wart
 - keratolytics
 - cryotherapy
 - cantharidin
 - Immunotherapy
 - IL Bleomycin
 - Laser
- Myxoid Cyst
 - Nodule drains fluid
 - Compresses matrix- groove



Malignant

- Melanoma
- SCC
- Bowens

Bowens disease

- Single nail,
- warty changes of nail fold
- ooze from edge of nail
- Inflammation and crusting